

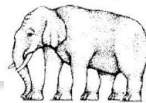
Beyond the Bruises: Identifying Child Abuse VS. Medical Mimics

Dena Nazer, MD
Medical Director, Kids TALK CAC
Professor, Wayne State School of Medicine

1

Objectives


- Recognize a variety of medical and non-medical conditions mistaken for child abuse
- Understand the complexity of the diagnosis in some cases and the need for consultation and coordination



2

Advice on Content


- Due to the content containing photos, I advise you watch this presentation on a screen and not while driving.
- This material contains optical illusions that may cause eyestrain for some viewers.
- It also includes photos some viewers may find distressing or triggering.
- It is ok to take a break and look away for a few seconds to relax your eyes.



3

Optical Illusions

- Give**
 - Give us a better understanding of how human visual perception works.
- Force**
 - Force us to recognize that what we see of the world is not a simple physical record like a photograph.
- Remind**
 - Remind us that our brain tries so hard to make sense of everything that it often finds meaning even where there is none, thus creating optical illusions.



4

4

Mimics of Child Abuse

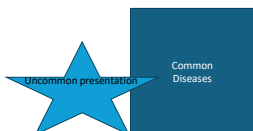
- Many diseases affecting the skin or unusual bruises may be mistaken for child abuse.
- This misdiagnosis could be due to:
 - unusual presentation of a common disease
 - rare disease
 - unfamiliarity with the disease
 - being misled by the social situation.



5

5

Disorders that mimic child abuse include uncommon presentations of common diseases and common presentations of uncommon diseases.

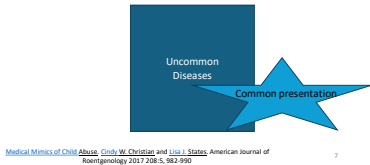


Medical Mimics of Child Abuse. [Cindy W. Christian](#) and [Lisa J. Stang](#). American Journal of Roentgenology 2017;208:5, 922-930

6

6

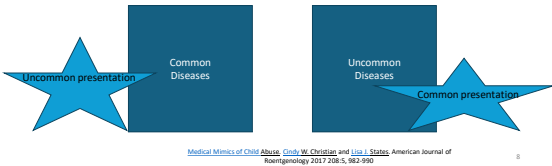- Disorders that mimic child abuse include uncommon presentations of common diseases and common presentations of uncommon diseases.



Medical Mimics of Child Abuse. Cook W, Christian and Liu J. States. American Journal of Roentgenology 2017;208:5, 902-909

7

- Disorders that mimic child abuse include uncommon presentations of common diseases and common presentations of uncommon diseases.




Medical Mimics of Child Abuse. Cook W, Christian and Liu J. States. American Journal of Roentgenology 2017;208:5, 902-909

8

Differentiating "Mimics" from Child Abuse

- Can be differentiated by:
 - "thorough" medical history
 - physical examination
 - laboratory testing
 - consultation with other specialties
 - collaboration with the multidisciplinary team members (LE, CPS,...)



9

Why is it important?

- We have an ethical responsibility to remain cognizant of abuse and to think carefully about diseases that mimic child maltreatment to :
- provide patients with appropriate medical care
 - protect families from the social and legal consequences of an incorrect diagnosis.

10

Differentiating Mimics of Child Abuse

- Differentiating these conditions from child abuse requires:
 - an awareness of alternative diseases
 - a willingness to consider alternative diagnoses
 - a recognition of social biases that affect medical decision making
 - an objective and rational approach to medical evaluation
 - an understanding of injury epidemiology, mechanisms, and consequences.

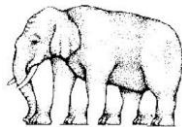
11

Remember!

The medical evaluation is only a piece of the full evaluation

"One only sees what one looks for. One only looks for what one knows"

Children with conditions mimicking child abuse may also be victims of abuse.



12

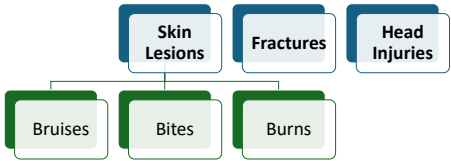
Cutaneous (skin) mimics of child abuse

Cutaneous lesions are the most common presenting manifestation of child abuse .

Many diseases and conditions affecting the skin may be mistaken for child abuse.

13

Manifestations of Physical Abuse in Children



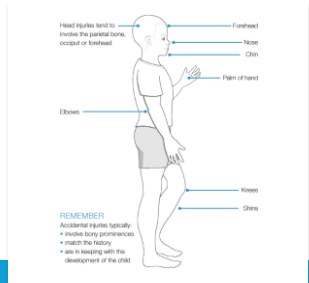
14

Bruises

- Common manifestation of physical abuse
- Keys to diagnosis
 - Child's development
 - Location
 - Pattern

15

Typical features of accidental injuries



16

16

An active 2-year-old girl



17

17




Rule 1: Those who don't cruise rarely bruise."

Sugar NF, Taylor JA, Feldman KW. Arch Pediatr Adolesc Med. 1999;153:399-403

18

18

TEN-4-FACESp
Bruising Clinical Decision Rule for Children < 4 Years of Age

<p>TEN Torso Ears Neck</p>  <p>FACES Frenulum Angle of Jaw Cheeks (<i>fleshy part</i>) Eyelids Subconjunctivae</p> <p>REGIONS</p>	<p>4 months and younger</p>  <p>Any bruise, anywhere</p> <p>INFANTS</p>	<p>Patterned bruising</p>  <p>Bruises in specific patterns like slap, grab or loop marks</p> <p>PATTERNS</p>
---	---	--


19

TEN-4-FACESp
Bruising Clinical Decision Rule for Children < 4 Years of Age

REGIONS **INFANTS** **PATTERNS**

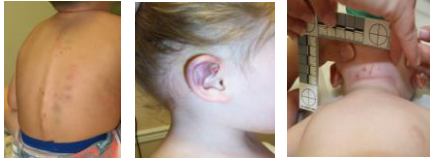20

TEN-4-FACESp
Bruising Clinical Decision Rule for Children < 4 Years of Age

<p>TEN Torso Ears Neck</p>  <p>FACES Frenulum Angle of Jaw Cheeks (<i>fleshy part</i>) Eyelids Subconjunctivae</p> <p>REGIONS</p>		
---	--	--

21

Regions



22

TEN-4-FACESp
Bruising Clinical Decision Rule for Children < 4 Years of Age

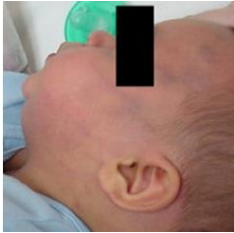<p>TEN Torso Ears Neck</p> <p>FACES Frenulum Angle of Jaw Cheeks (<i>fleshy part</i>) Eyelids Subconjunctivae</p> <p>REGIONS</p>	<p>4 months and younger</p> <p>Any bruise, anywhere</p> <p>INFANTS</p>	<p>Patterned bruising</p> <p>Bruises in specific patterns like slap, grab or loop marks</p> <p>PATTERNS</p>
---	---	--

23

TEN-4-FACESp
Bruising Clinical Decision Rule for Children < 4 Years of Age

<p>4 months and younger</p> <p>Any bruise, anywhere</p> <p>INFANTS</p>

24



25

25

TEN-4-FACES_p
Bruising Clinical Decision Rule for Children < 4 Years of Age


Patterned bruising

Bruises in specific patterns like slap, grab or loop marks

PATTERNS

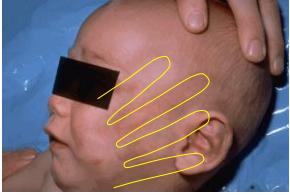
26

26



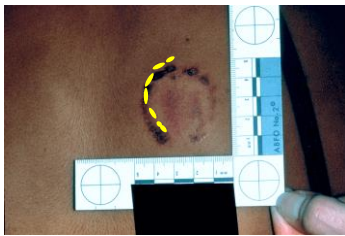
27

Bruise with recognizable shape



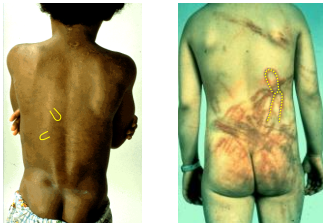
28

Bruise with recognizable shape



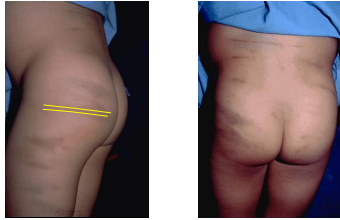
29

Bruise with recognizable shape



30

Bruise with recognizable shape



31

TEN-4-FACESp
Bruising Clinical Decision Rule for Children < 4 Years of Age

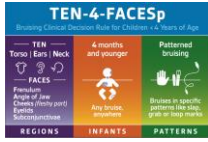<p>TEN Torso Ears Neck</p> <p>FACES Frenulum Angle of Jaw Cheeks (fleshy part) Eyelids Subconjunctivae</p> <p>REGIONS</p>	<p>4 months and younger</p> <p>Any bruise, anywhere</p> <p>INFANTS</p>	<p>Patterned bruising</p> <p>Bruises in specific patterns like slap, grab or loop marks</p> <p>PATTERNS</p>
--	---	--

32

TEN-4-FACESp

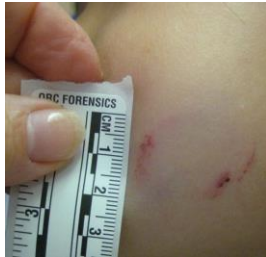- TEN-4-FACESp is a useful acronym to help screen children under 4 years of age with bruising to identify when a bruise is more likely to be caused by abuse than accidental injury
- TEN-4-FACESp is not to diagnose abuse but to function as a screening tool to improve the recognition of potentially abused children with bruising who require further evaluation.
- If bruising in any of the three components (Regions, Infants, Patterns) is present without a reasonable explanation, strongly consider evaluating for child abuse and/or consulting with an expert in child abuse.

33



34

A 5-year-old with a "bite mark"

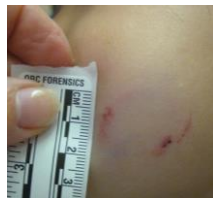

35

35

A scooter mark

- A 5-year-old girl with limited English.
- School reported bite mark.
- She reported she fell and the end of scooter handle hit her in cheek. Careful assessment reveals the non-abusive nature of this mark.



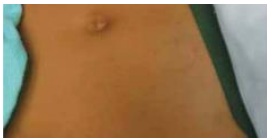AAP Visual Diagnosis of Child Abuse

36

BiKe mark
not
BiTe mark



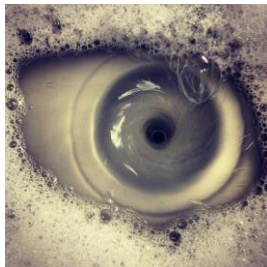37



Is this a bite mark

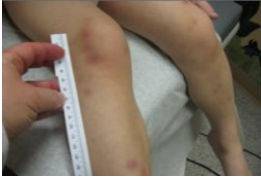38

Eye? Maybe a
draining sink!



39

- This child reported in school that he would get hit by his brother.



40

Idiopathic thrombocytopenic purpura.

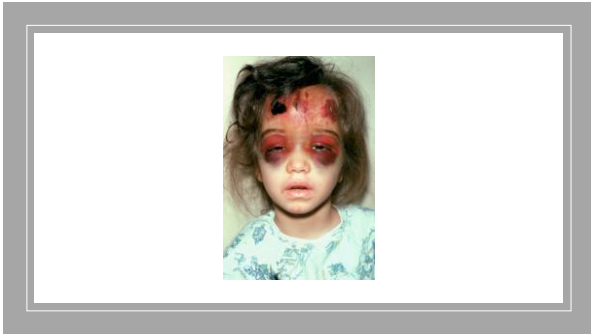- Complete blood and platelet count revealed thrombocytopenia, and he was ultimately diagnosed with idiopathic thrombocytopenic purpura.
- Clues to a coagulopathy include petechiae at clothing line pressure sites; bruising at sites of object pressure, such as in the pattern and location of infant seat fasteners; and excessive diffuse bleeding if the child has a severe bleeding disorder.
- The presence of a bleeding disorder does not rule out inflicted injuries.

41


Evaluation of Possible Bleeding Disorders

- A complete history is critical in distinguishing between abusive injuries and cutaneous bleeding from a bleeding disorder.
- Laboratory testing suggesting the presence of a bleeding disorder does not rule out abuse. Children with medical conditions can be abused!
- If a laboratory evaluation is planned, initial testing should be guided by the prevalence of the condition being considered.
- Consultation with a hematologist should be considered, especially if initial screen is abnormal.


42



43




44



- Our eyes naturally follow the powerful vertical lines.
- Because we are trying to rationalize either the black or white vertical lines, we cannot make sense of the untidiness of the columns and, to our eyes, the horizontal lines are sloping downwards.

45

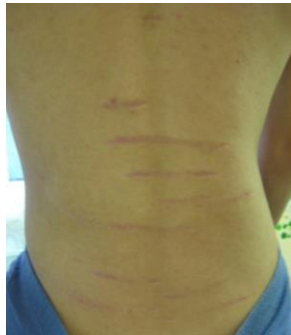

Children with horizontal lines!

46

Horizontal Lines

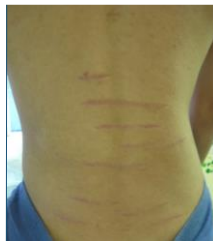- A teenager was referred by CPS when his younger brother disclosed physical abuse (hit with a belt).
- The teen was not able to explain the marks and claimed that he was not aware of their presence.



47

Striae (stretch marks)

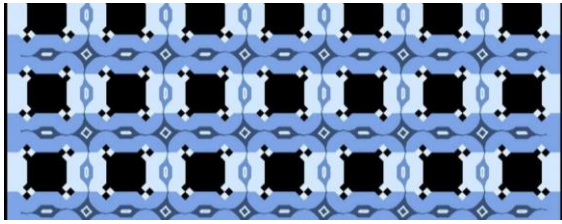
- Striae distensae are depressed lines or bands of thin, reddened skin that later become white, smooth, shiny, and depressed.
- They occur in response to changes in weight or muscle mass and skin tension.
- A clue to the diagnosis is the location in the natural skin lines.



ASP Visual Diagnosis of Child Abuse/ Courtesy of James Hoffman-Rosenfeld, MD.

48 48

48

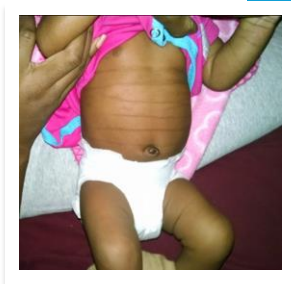


More children with horizontal lines!

49

More horizontal lines

- A report to child protective services was made when linear marks were noted on the body of the baby.



AFP Visual Diagnosis of Child Abuse. Courtesy of Lori Fromm, MD

50

Transient Pigmentary Lines of the Newborn

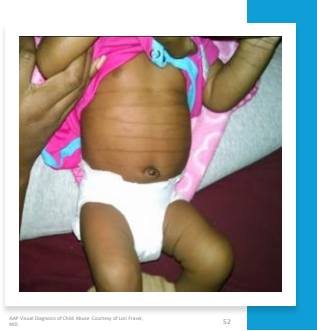
- Transient pigmentary lines of the newborn is a rare but benign skin condition that self-resolves within 2 to 6 months.
- This hyperpigmentation of the skin typically appears at birth or shortly thereafter and often involves the abdomen, back, and extremities.

Huang J, Maeda A. Transient pigmentary lines of the newborn. Consultant. 2003;19(4):404-406.

51

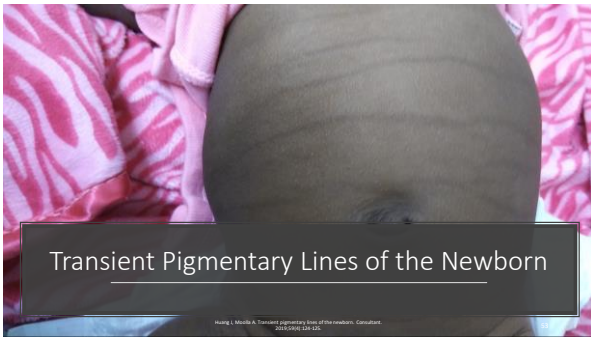
Transient Pigmentary Lines of the Newborn

- May be mistaken for inflicted linear marks, e.g., belt, cord.
- The clue is the location in the flexural creases.



52 Visual Diagnosis of Child Abuse Courtesy of Lori Pincus, MD

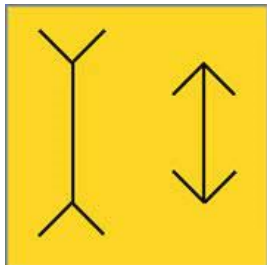
52



Huang J, Moolji A. Transient pigmentary lines of the newborn. Consultant. 2016;196:28-30.

53

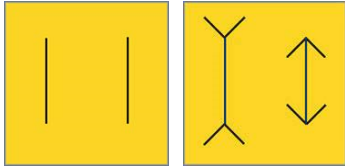
Which line is longer?



54

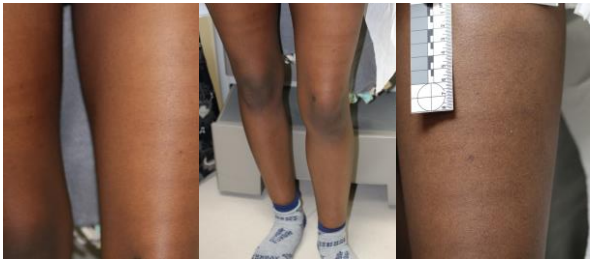
54

Both the same length



55

55




A teen who loves watching Criminal Minds and would love to work in forensics was referred to our CAC for an evaluation (sexual abuse and human trafficking).


56



57



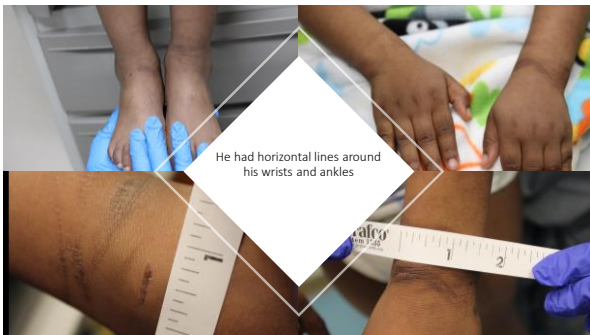
58



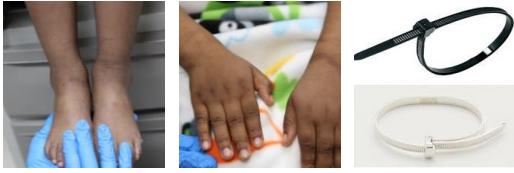More Horizontal lines

- A 6-year-old future judge.
- He was found in a camper by the police with his 2 sisters.
- CO: I am already invited for coffee in his future chambers.

59



60



Further history

- He disclosed he was tied with zip ties around his wrists and ankles and tied to a chair.
- Ligature marks would be abusive when a child is restrained with a rope or cord being tied around a body part, most commonly an extremity.
- Diagnosis: ligature marks/ physical abuse

61

Remember the full picture...

- **Physical assaults:**
 - He disclosed his mother, and her boyfriend would beat on him all the time with a belt and sticks
 - Sometimes he got punched.
 - He was exposed to prolonged environmental cold when he was left outside.
 - He was in forced restraint and in maintenance of an uncomfortable position when he was tied with zip ties used to tie his wrists, his ankles and tied to a chair.
- **Isolation:** He was removed from school and outside activity, and he was restricted from seeing family members.
- **Intimidation and emotional/psychological maltreatment:** He was repeatedly called a "cry baby" for crying and was called "greedy" when asking for food. His mouth was also duct-taped because he was told he talks too much.
- **Deprivation:**
 - He was deprived of food and water and only fed once a day.
 - He was made to sleep on the floor (no pillow or blanket).
 - He was also deprived of safe and hygienic excretory function and made to urinate in a bottle and was not allowed to use the bathroom.
 - He also had not seen a physician or dentist, not been to school for months, and deprived of human contact.
 - This adds to the diagnosis of neglect of medical needs, neglect of mental health needs, deprivation of education, deprivation of human contact.


62

Final diagnosis: Medical Torture


At least two physical assaults, occurring over at least two incidents or a single extended incident, which would cause prolonged physical pain, emotional distress, bodily injury, or death

At least two elements of psychological abuse such as isolation, intimidation, emotional/psychological maltreatment, terrorizing, spurning, or deprivation inflicted by the child's caretaker(s).

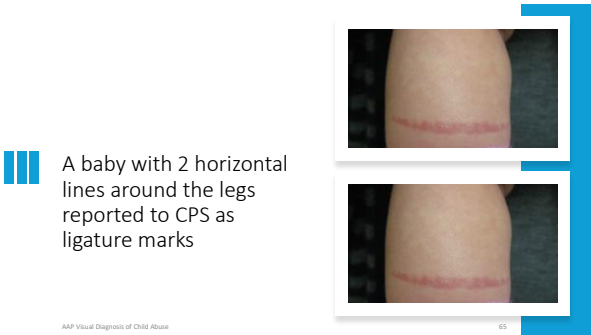Neglect is usually present



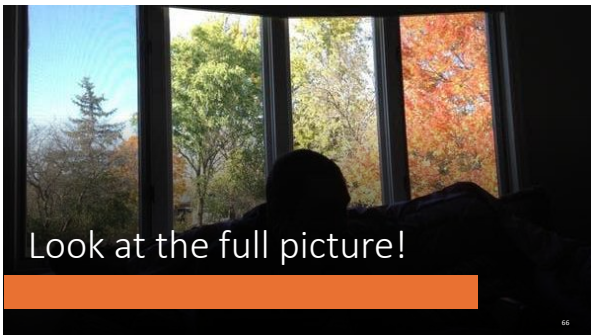63




64



65



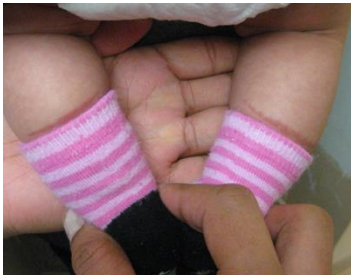66



Close-up assessment reveals the fine pattern of the knitted sock.

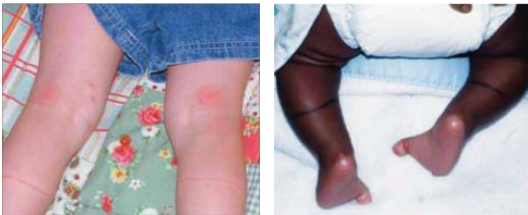67

67



68

68



Nazar and Smyth. Cutaneous conditions mimicking child abuse

69

69

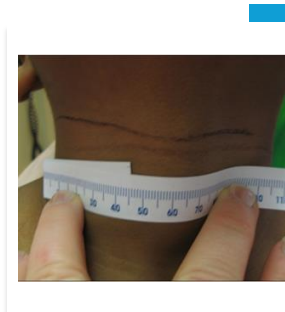
Always have good lighting when doing your evaluations



70

70

A 5-year-old with a "strangulation" mark around his neck



71

AAP Visual Diagnosis of Child Abuse

71

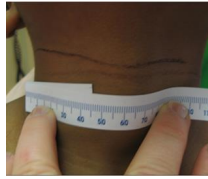


72

72

Non-abusive Rope Injury on Neck

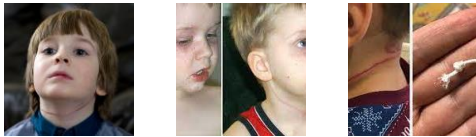- Careful history is necessary to elucidate the etiology of the injury.
- Incidents such as this are obvious to anyone who was around and should be presented in the initial history by the child or family.



AAP Visual Diagnosis of Child Abuse

73

73

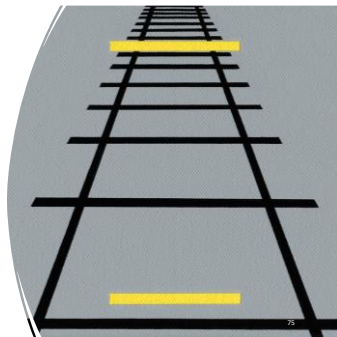


Many mothers sharing photos online...

74

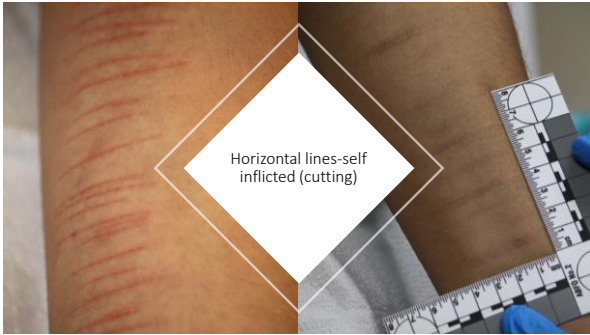74

More lines ...



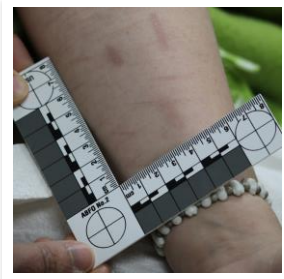75

75

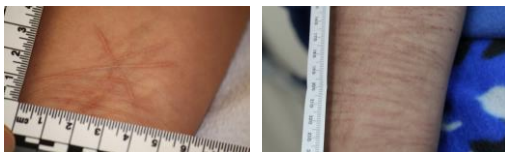

76

Horizontal and vertical lines (cutting)

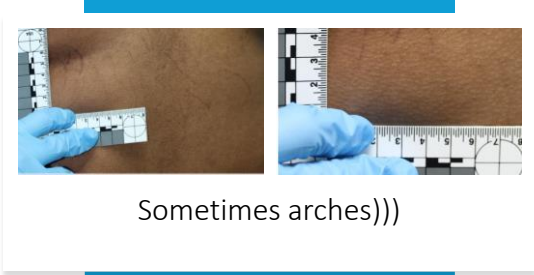

77

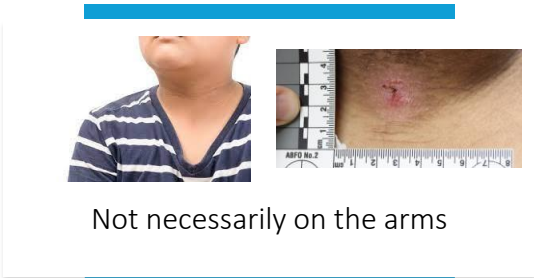

Horizontal, vertical, and across lines (cutting)


78



79



80

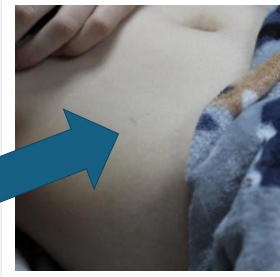


81



82

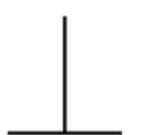Same child
Always ask! Not always
Zelda!
*"My grandpa "sliced"
me with a knife!"*



83

83

Which line is
longer? the
horizontal?
or the vertical
line?




84

84



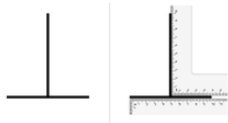
Both the same length!
Your eyes scan horizontal lines
more easily than vertical ones
The vertical line divides the
horizontal one into two smaller
segments.



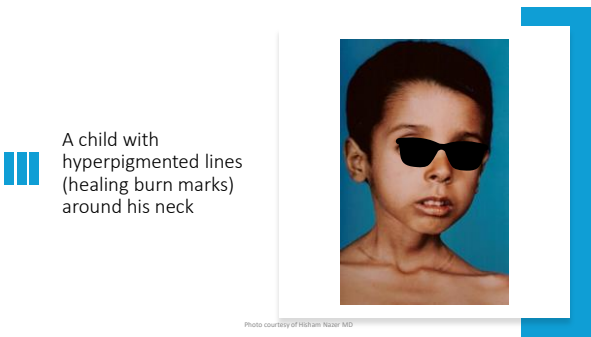
85



More children
with
“concerning”
lines!



86



III A child with
hyperpigmented lines
(healing burn marks)
around his neck


Photo courtesy of Hisham Nizar MD



87



More history reveals:
child has failure to thrive
and poor appetite. Burns
are part of a cultural
practice of Maqwa



88

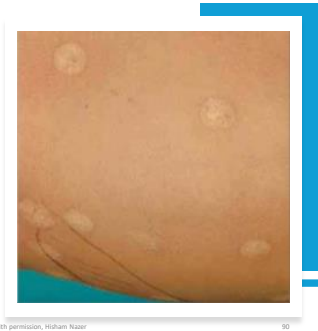
Maquas (cultural burning)

- 'Maquas' are burns that are inflicted with hot metal spits or coals near an area of illness or pain. It is part of Bedouin (Arabic), Russian, and Druse cultural practices

20 89

89

'Therapeutic'
burns in a patient
with glycogen
storage disease.

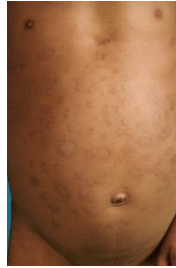

With permission, Hisham Nazer 90

90

'Therapeutic' burns in a patient with recurrent abdominal pain.

Seen in Detroit on a 9-year old's abdomen (from Yemen).



With permission, Hisham Nazer

91

What do the cup, spoon, and coin have in common?



92

92

They are all part of cultural practices that may mimic child abuse!

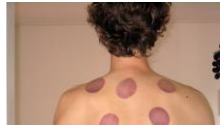
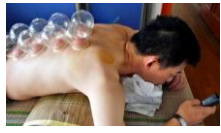
93

93

Cupping

Cupping marks induced by suction from a heated cup placed on the skin. These marks are caused by suction. Despite their alarming appearance, they represent a folk healing practice.

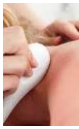

94

94

Coining or Spooning

- Coins or porcelain spoons
- Warm or mentholated oil applied to chest
- Coin or spoon rubbed vigorously
- Back, shoulders, chest
- Linear lines of petechiae and ecchymoses
- Used for a variety of ailments—colds, flu, fever, myalgias



95

95

It's a small world after all!

- The song is played on average 1,200 times a day.
- Since this ride is in all the Disney Parks around the world, the theme song is now played somewhere on the planet every hour of the day.



96

96

Culture swims across the finish line
Rio 2016



shutterstock.com - 184794882

25

97



Michael Phelps

Cupping marks can be seen on the athlete's shoulders as he competes in the final (2016)

98




No way to
keep up with
all cultures!



99



You continue to think and read and research!



100

100

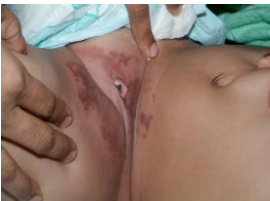

Is this child abuse or merely garlic?



101

101



A 16-month-old baby referred to the child protection team for suspected abuse due to a burn of unknown etiology

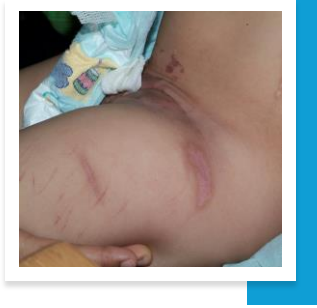

With permission, Consultant for Pediatricians; photo: Dena Nazer et al.

102



- With permission, Consultant for Pediatricians; photo: Dena Nazer et al.



103

Further history

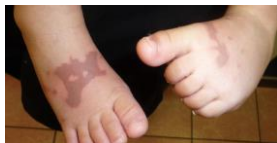- The mother had called the grandmother in Mexico regarding the suspected insect bite.
- The grandmother advised using crushed garlic applied as a poultice and applying it to the groin area
- The mother did that over night

104

104

More garlic! Also, the grandmother's advice!

- An 11-month-old boy presented with purplish discoloration of the feet.
- The infant had had a cold for 2 days.
- Before bed the night before, the father had applied chopped garlic bulbs to the infant's feet and had wrapped them with bandages as treatment.



Consultant; Volume 12 - Issue 6 - June 2013

105

105

Garlic

- Garlic (*Allium sativum*) is thought to have been used as early 3000 BC for a multitude of disorders, and a local application of it is a traditional remedy for local pain.
- Garlic is still used as a folk medical therapy or an herbal remedy.
- Fresh garlic can be a potent irritant under occlusive conditions, especially in the crushed form.
- One of many possible adverse reactions is allergic contact dermatitis, which usually is an epidermal reaction. Diallyl disulfide, allyl propyl disulfide, and allicin are the principal allergens.

106

106

Garlic

- Diallyl disulfide can cause superficial burns to the skin, as it did with the infant in our case.
- At times it can cause second-degree burns with the presence of bullae.
- Young children are especially susceptible, because the skin is delicate and does not have enough keratinous material in the outer layer of the epidermis to protect against this agent.
- Comparatively, infants may require 6 to 8 hours of exposure to induce a chemical burn, whereas a longer duration is required in adults.

107


107

Table-Brief review of reported cases of garlic burns

Study	Patient's age	Reason for applying garlic	Duration of application	Area of application
Ferns	17 months	Advised by a naturopathic physician to treat diarrhea and fever	8 h	Both feet
Geis	6 months	Advised by the grandmother to treat aseptic meningitis	6 h	Wrists
Candlish	6 years	Grandmother applied it to treat erosion from shoe	2 days	Foot
Farnell	29 years	Unknown/ not stated	18 h	Chest and abdomen
Hilberg	38 years	treat suspected candidal infection breast	2 days	Breast
Hafner	3 months	Advised by a relative to treat a cold	8 hours	Ankles and feet
Hess	42 years	To treat chronic knee pain	3 h	Knee
Reardon	50 years	Advised by herbal healer to treat asthma	8 h	Forehead
Leichter	7-year 18-year old	Self-inflicted (to be excused from work)	not reported	Knees, ankles, feet
Deer	60 years	for chronic diabetic neuropathy	12 h	feet

The Aha Moment!

108



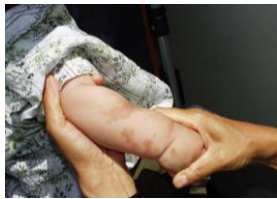Lemons and Limes!



109

Grabbed too hard?

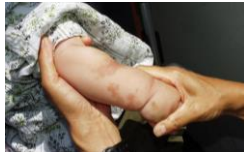- An 8-month-old with "grab marks" on his forearm



110

Phytophotodermatitis

- He presented 2 weeks after fruit juice was dripped onto skin (pear, peach, pineapple, cherry).
- This is a phototoxic reaction that occurs when psoralens, compounds found in plants such as lemons, limes, mangoes, figs, and celery, remain on skin that is later exposed to ultraviolet light.



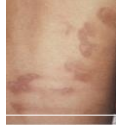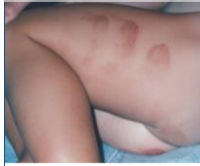111

Phytophotodermatitis

Cutaneous reaction caused by light-sensitizing botanical substances and ultraviolet light, e.g., citrus juices (e.g., limes) eaten in the sunshine.

Parent may have material on hands and touch a child, leaving handprint pattern on the skin. Marks can look like bruises or burns.

The eruption may range in severity from mild erythema to severe blistering



AAP Visual Diagnosis of Child Abuse

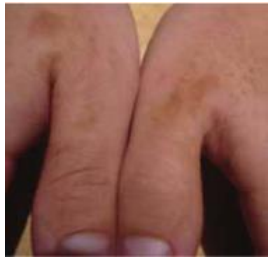112

112

112

Phytophotodermatitis

- This teenager had rapidly developing dark spots over her hands after handling limes and lemons while preparing "Margaritas."
- She then went to the beach. The lesions lasted 3 weeks and slowly faded without treatment.

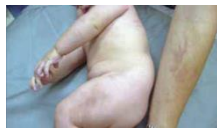

113

113

Phytophotodermatitis

- A child with phytophotodermatitis.
- Notice how the marks resemble handprints after the baby was held by his mother.
- His mother also had similar lesions..

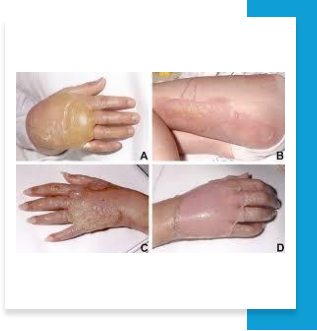

Photographs courtesy of Tor A. Shweydt

114

114

phytophotodermatitis




115




116

Tree? Broccoli?



117

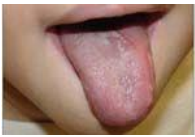A "burning" or "burnt" tongue!



118

118

A "burning" or "burnt" tongue!



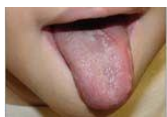- A healthy 4-year-old girl presented to the emergency department (ED) with suspected inflicted burns on the tongue. Initially, the patient had complained of a burning mouth to school staff.
- The diagnosis was cigarette burns.
- CPS referred the patient to an abuse specialist for a second opinion.

Consulted by Professionals, photograph courtesy of Sachina Nuthakki et al.

119

119

Diagnosis: Geographic tongue



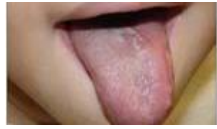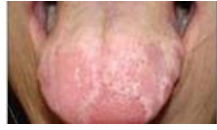- The mother reported the child's oral lesions had been present for quite some time.
- Only their location and severity had changed.
- At the time of the evaluation, the patient was able to eat and drink normally.
- Physical examination results were normal except for a red plaque on the tongue with a well-demarcated irregular white border.
- The lesion was nontender. There were no other indications of abuse.

120

120

Differentiating factors in this child
Geographic tongue vs. cigarette burn

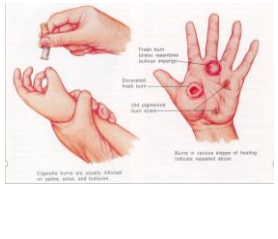
- The mother had similar lesions
- The characteristic migration of the lesions.
- Burn components, such as eschar and signs of tissue coagulation not present.



121

121

Cigarette Burns

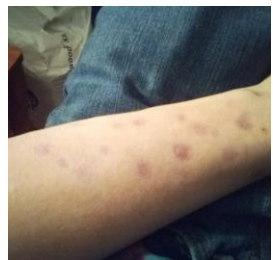

122

122

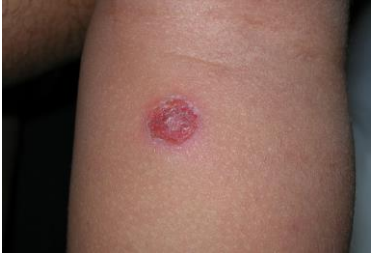Cigarette Burns

- Cigarette burns are one of the most common abusive object burns.
- These characteristically form a sharply-demarcated, round eschar with a surrounding collaret of tissue reaction.
- These are self-inflicted cigarette burns



123

123



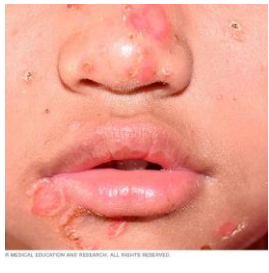Suspected
Cigarette
burn

124

124

Impetigo (im-puh-TIE-go)

- A common and contagious skin infection that mainly affects infants and young children.
- It usually appears as reddish sores on the face, especially around the nose and mouth and on the hands and feet.
- Over about a week, the sores burst and develop honey-colored crusts.

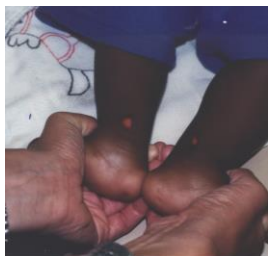

125


125

More suspected cigarette burns

- A 5-month-old infant with abrasions on the inner ankles after a day with the babysitter. It was suspected that he had been burned with a cigarette.

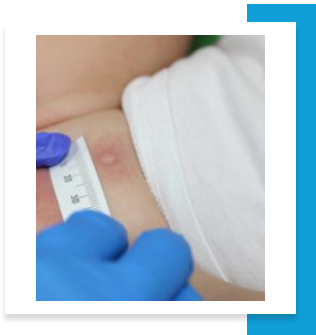

126




127

||| Suspected physical abuse and suspected sexual abuse in an infant! (healed impetigo)



128

||| Burns on the Buttocks (photos of buttocks to follow)



129

(photos of the buttock to follow)

130

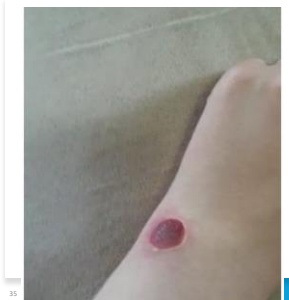
When it feels unreal, it may be so



131

When it feels unreal, it may be so

- A 9-year-old girl presented with an abrasion on her left wrist. No history of trauma. She's had multiple abrasions appear on her wrists over the past 2 weeks.
- Further history : she was on vacation spending most of her time at home



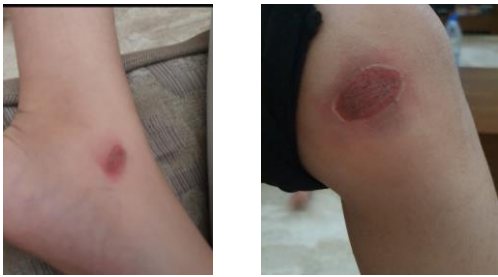132



And she sent the video of exactly how she does it!

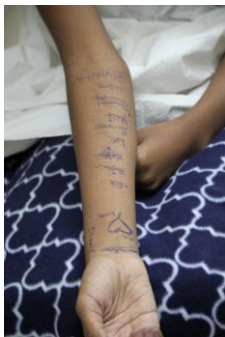133

133

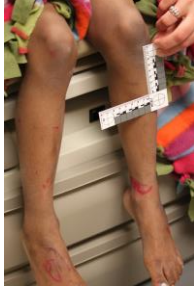

134

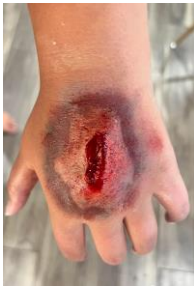134



135



136



137

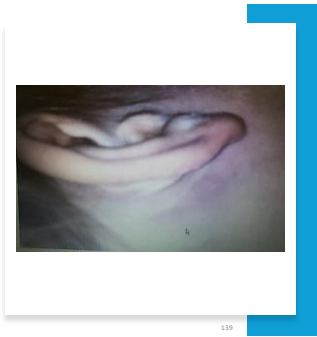
Courtesy of Lily Andrews 12 years old- 2025

An urgent
consultation! For
urgent bruises!

138

138

III A 19-month-old child with bruises behind the ear with no history of trauma



139

TEN-4-FACESp
Bruising Clinical Decision Rule for Children < 4 Years of Age

<p>TEN Torso Ears Neck</p> <p>FACES Frenulum Angle of Jaw Cheeks (fleshy part) Eyelids Subconjunctivae</p> <p>REGIONS</p>	<p>4 months and younger</p> <p>Any bruise, anywhere</p> <p>INFANTS</p>	<p>Patterned bruising</p> <p>Bruises in specific patterns like slap, grab or loop marks</p> <p>PATTERNS</p>
--	---	--

140

140

Further history

No history of trauma

His mother noted them in the evening and called his pediatrician

The pediatrician emailed me to call her ASAP

We discussed the seriousness of bruising behind the ear,...etc

I recommended a full exam and skeletal survey

The pediatrician planned a telehealth visit to explain to the mother what to expect

141

141

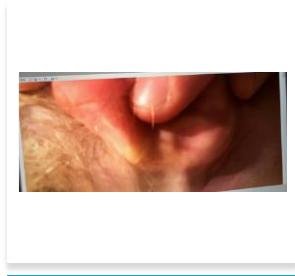Diagnosis:
PAINT



142

142

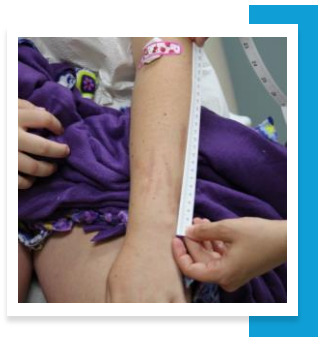Photo after wiping off the paint: the pediatrician did a virtual visit and saw the mother wipe off the paint.



143

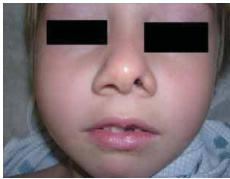143

From erasing too!



144


Deformed nose from excessive nose picking



145

145

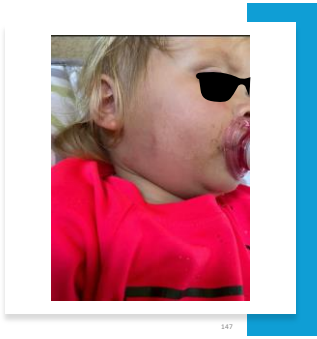
Wish it kept its head in the sand!



146

146

A baby with a bruise on her cheek





147

147

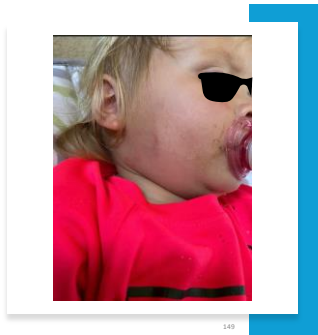
TEN-4-FACESp

Bruising Clinical Decision Rule for Children < 4 Years of Age


<p style="margin: 0;">TEN</p> <p style="margin: 0;">Torso Ears Neck</p>	<p style="margin: 0;">4 months and younger</p>	<p style="margin: 0;">Patterned bruising</p>
<p style="margin: 0;">FACES</p> <p style="margin: 0;">Frenulum Angle of Jaw Cheeks (<i>fleshy part</i>) Eyelids Subconjunctivae</p>	 <p style="margin: 0;">Any bruise, anywhere</p>	 <p style="margin: 0;">Bruises in specific patterns like slap, grab or loop marks</p>
<p style="margin: 0;">REGIONS</p>	<p style="margin: 0;">INFANTS</p>	<p style="margin: 0;">PATTERNS</p>

148

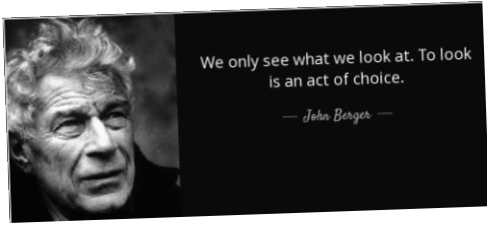
Diagnosis: beak mark!



149



150



151



152



153



154

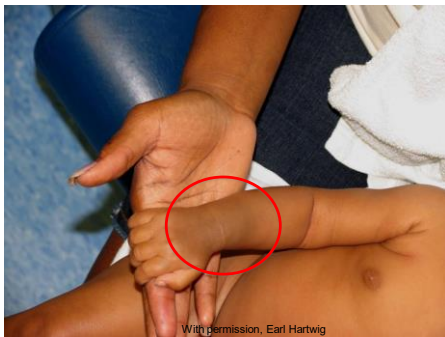154

Bruises all over!

- A 6-month-old baby girl brought for examination by child protective services due to bruising noted at a childcare facility.
- Examination reveals numerous large similar areas to the buttocks and lower back, as well as extremities.

155

155

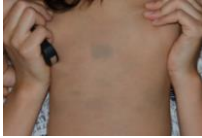

With permission, Earl Hartwig

156

Congenital Dermal Melanocytosis

Also called slate gray nevus/macule/patch/spot, formerly known as Mongolian spots



157

Congenital Dermal Melanocytosis

- Occur in 89-90% of African-Americans and 10% white infants.
- Most fade by age 5yr
- Usually present at birth
- No swelling or redness
- Will look the same several weeks later as opposed to bruises

158

Dermal Melanocytosis and Inflicted Patterned Injuries

- Children may have a mixture of abusive injuries and "mimics."
- This child has clearly patterned injuries: linear tram-track marks and unusual circular marks.
- The child also has sacral dermal melanocytosis, a normal finding.

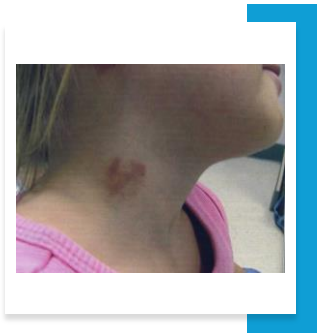159

Referred by the school

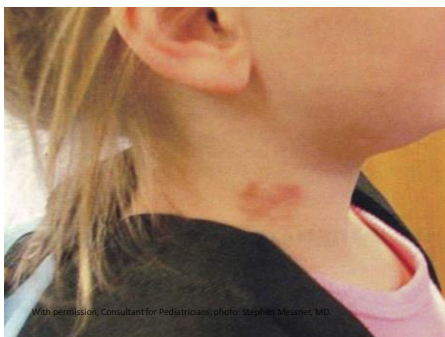

160

Suspected sexual abuse

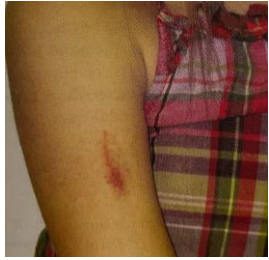

161



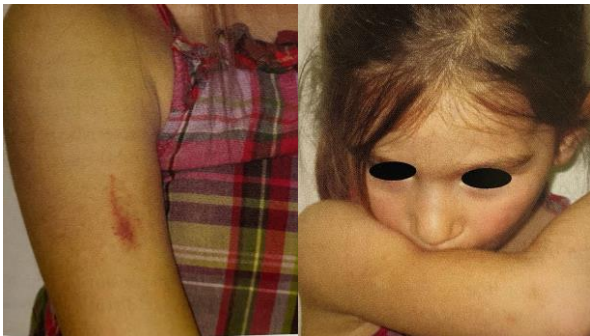162

|| Don't forget to ask the child how it happened?



163

163



164

|| Sometimes we are not sure what we're looking at and that's ok!



165

165

Sometimes we are not sure what we're looking at and that's ok!

- A 5-year-old girl was referred from her pediatrician's office to the emergency department
- Her mother noticed black spots and what looked like bleeding in her private part area when she came back from a visit to her father's home
- The exam was documented as "abnormal" in the ED, and she was referred to our CAC for a follow up evaluation

166

Lichen Sclerosus

- Inflammatory dermatologic condition of young girls and postmenopausal women
- Characteristic appearance
 - Thinned, pale, atrophic, friable skin.
 - Figure-of-8 appearance around perineum and anus.
 - Fissuring is common with small broken blood vessels.
- Symptoms
 - Some girls are asymptomatic.
 - Can have pruritus and dysuria, vulvar pain, or constipation, painful defecation.


167

Lichen Sclerosus (continued)

- Treatment
 - High-potency topical corticosteroids with taper.
 - Recurrence rate of 44% to 82%.
 - No clear guidance in literature regarding course of disease in children.
 - Some patients experience complete resolution.

168

Remember!



169

Teaching points

- There are a variety of conditions that can be mistaken for bruises or burns.
- Always evaluate alternative explanations when abuse is being considered, especially when there are unusual lesions inconsistent with classic abuse patterns.
- In some cases, alternative explanations can be excluded based on history, physical examination, and basic laboratory findings; however, certain conditions may require sophisticated testing and referral to a consultant for definitive diagnosis.
- Some cultural practices are associated with inflicted lesions; the degree of injury, presumed intent, and the cultural acceptability of the practice need to be considered in making an abuse assessment.

170

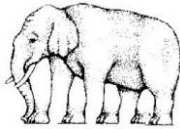
Avoiding Misdiagnosis

- Know the mimics of child abuse.
- Take complete histories.
- Do complete physical examinations.
- Order appropriate laboratory and radiographic studies.
- Multidisciplinary consultation may be necessary with pediatric gynecologists, urologists, surgeons, and child protective services.
- Review and keep up-to-date on the literature.

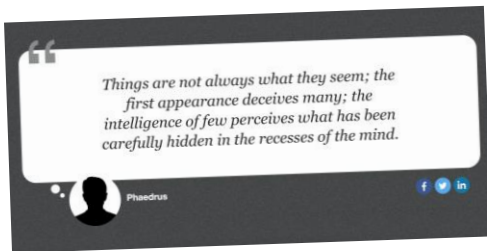
171

Remember!


- The medical evaluation of a child for abuse requires a wide differential diagnosis encompassing medical mimics as well as non-abusive mechanisms of traumatic injury.
- The medical evaluation is only a piece of the full evaluation
- Somethings we may never know! and we have to be comfortable with that!



172



173



174
